

A novel *PORCN* mutation in a severe case of Focal Dermal Hypoplasia

Ramirez-Botero

Severe case of Focal Dermal Hypoplasia

Andres Felipe Ramirez-Botero(1), Sabrina Eichler(2), Arndt Rolfs(2), Harry Pachajoa(1)

1. Department of Basic Sciences, Icesi University, Street 18 #122-135, Cali, Colombia
2. Centogene AG, Schillingallee 68, Rostock, Germany

Corresponding author:

Harry Pachajoa

Department of Basic Sciences, Universidad Icesi, Street 18 #122-135, Cali, Colombia

Fax: +5725552334 ext 8077

Telephone: +5725552334 ext 8075

hmpachajoa@icesi.edu.co

This article has been accepted for publication and undergone full peer review but has not been through the copyediting, typesetting, pagination and proofreading process, which may lead to differences between this version and the Version of Record. Please cite this article as doi: 10.1111/cga.12146

This article is protected by copyright. All rights reserved.

Abstract

Focal dermal hypoplasia is a rare genetic disease characterized by abnormalities of ectodermal and mesodermal derivatives. This is the case of an eight year old female who seeks genetic counseling for multiple malformations, aggressive behavior and intellectual disability. Gene analysis confirmed focal dermal hypoplasia.

Key words

Focal dermal hypoplasia, *PORCN* gene, intellectual disability

Introduction

Focal dermal hypoplasia (MIM #305600, FDH), is an unusual genetic disease that affects ectodermal and mesodermal derivatives (Mallipeddi et al 2006, Reddy & Laufer 2009, Sacoor & Motswaledi 2005, Suskan et al 1990, Jones et al 2013). It is inherited as an X-linked dominant disease with females accounting for 90% of affected individuals (Jones et al 2003). It has been determined that 5% of the affected females inherit this disease from their parents (usually the mother), since 95% of them have *de novo* mutations (Jones et al 2003, Larrègue & Duterque 1975). The incidence of the disease is unknown (Sutton and Veyver, 2013).

Case report

This is the case of an eight year old female from Colombia with multiple congenital malformations. She is the daughter of healthy unrelated parents, without any familial history of genetic diseases; at the time of pregnancy the mother was 23 and the father was 30 years old. She was born at 32 weeks via cesarean delivery with perinatal hypoxia that required a long term hospitalization.

At the age of eight years, the patient was referred to genetic counseling and physical examination revealed severe intellectual disability and evidence of auto and heteroaggressive conducts; additionally, a weight of 12 kg, a height of 104 cm and a cephalic perimeter of 43 cm (all below $<P_3$). The patient exhibited facial asymmetry, left microphthalmia, low set dysplastic ears, a narrow auditory canal, bifid lower lip, oligodontia, an arborescent papilloma in the mental region, prognathism and pointed chin, anteverted nares, a narrow nasal bridge and sparse hair with patchy alopecia (figure 1). Moreover, the examination revealed generalized atrophy of the skin, syndactyly of the third and fourth finger of the right hand, a split left hand (figure 2), a cleft right foot and adactylia of the left hallux. The patient brought a brain tomography at age six with normal results. Due to severe cognitive impairment, it was not possible to determine her intellectual quotient by any battery; however, the Barthel Index determined total dependence.

Genetic analysis and results

Genetic analysis was performed on high quality purified DNA. Bidirectional Sanger sequencing of the entire coding region and the highly conserved exon-intron splice junctions was performed with gene and amplicon specific primers. PCR is followed by Shrimp Alkaline phosphatase / exonuclease I treatment, following cycle PCR is carried out using BigDye Terminator kit v3.1 (ThermoFisher Scientific, Waltham,

MA, USA) and subsequent purification. Sequencing was performed using ABI 3730xl sequencer (ThermoFisher Scientific, Waltham, MA, USA). The test has been developed and validated by *Centogene AG* for clinical purposes only. Reference sequence is of *PORCN* gene is NM_203475.2.

The heterozygous nonsense mutation NM_203475.2(PORCN):c.67C>T(p.Gln23*) was detected in exon 2 on the patient genetically diagnosing FDH (figure 3); the gene analysis for the mother was normal.

Discussion

FDH is a rare disease whose clinical features include atrophy and linear pigmentation of the skin, localized cutaneous deposits of superficial fat, papillomas in the mucous membranes or in the skin, digital anomalies, oral abnormalities, ocular anomalies and in 15% of the cases intellectual disability (Mass et al 2009, Sutton & Veyver 2013).

The patient carries the novel heterozygous mutation NM_203475.2(PORCN):c.67C>T(p.Gln23*) (Arias-Llorente 2015, Bornholdt et al 2009, Clements et al 2009, Clements et al 2008, Leoyklang et al 2008, Lombardi et al 2011). Table 1 evidences the phenotypic similarities between the patients described by Maas and collaborators (Mass et al 2009) and the patient in the present report; nevertheless, the patient exhibits severe intellectual impairment which is not a common finding. FDH does not exhibit an evident genotype-phenotype correlation (Mass et al 2009). After considering she has a normal brain CT scan, the severe intellectual disability can be due to prematurity, perinatal hypoxia, complications derived from a prolonged hospitalization after birth and the lack of schooling.

Patients with FDH and their families must receive genetic counseling and a parental carrier testing; in this case, confirming a *de novo* mutation in the patient. It is imperative to consider that in familial cases, affected females inherit this mutation from the mother (Shimaoka et al 2009). During conception, there is a 50% risk that the mutant allele for *PORCN* will be transmitted, and if one takes into account that most male fetuses will be spontaneously aborted, the expected outcomes of the pregnancy are the following: 33% unaffected females, 33% affected females and 33% unaffected males; on the contrary, if the affected female has a somatic mosaicism mutation, the risk of her descendants maybe as high as 50% (Sutton & Veyver 2013). On the other hand, affected males have a somatic mosaicism for mutations in *PORCN*; hence, the risk of affected daughters is as high as 100% and for sons is 0% (Sutton & Veyver 2013).

When comparing literature of previously reported FDH cases to the present case, many phenotypical similarities are observed; however, severe intellectual disability and auto/heteroaggressive behaviors are not common. This leads to the question if this new undocumented mutation is related with such traits.

Disclosures.

None.

References

Arias-Llorente RP, Rodriguez-Dehli C, López-Martínez A, et al. Focal Dermal Hypoplasia Due to De Novo Mutation c.1061T>C(p.Leu354Pro) in the *PORCN* Gene: Importance of Early Diagnosis and Multidisciplinary Follow-Up. *Fetal Pediatr Pathol.* 2015;1-8. [Epub ahead of print]

Bornholdt D, Oeffner F, König A, et al. *PORCN* mutations in focal dermal hypoplasia: coping with lethality. *Hum Mutat.* 2009;30:E618-28.

Clements SE, Mellerio JE, Holden ST, et al. *PORCN* gene mutations and the protean nature of focal dermal hypoplasia. *Br J Dermatol.* 2009;160:1103-9.

Clements SE, Wessagowit V, Lai-Cheong JE, et al. Focal dermal hypoplasia resulting from a new nonsense mutation, p.E300X, in the *PORCN* gene. *J Dermatol Sci.* 2008;49:39-42.

Froyen G, Govaerts K, Van Esch H, et al. Novel *PORCN* mutations in focal dermal hypoplasia. *Clin Genet.* 2009;76:535-43.

Jones KL, Jones MC, Del Campo M. 2013. Smith's recognizable patterns of human malformation. 7th edition. Philadelphia: Elsevier Saunders.

Larrègue M, Duterque M. 1975. Letter: Striated osteopathy in focal dermal hypoplasia. *Arch Dermatol* 111(10):1365.

Leoyklang P, Suphapeetiporn K, Wananukul S, et al. Three novel mutations in the *PORCN* gene underlying focal dermal hypoplasia. *Clin Genet.* 2008;73:373-9.

Lombardi MP, Bulk S, Celli J, et al. Mutation update for the *PORCN* gene. *Hum Mutat.* 2011;32:723-8.

Mallipeddi R, Chaudhry SI, Darley CR et al. 2006. A case of focal dermal hypoplasia (Goltz) syndrome with exophytic granulation tissue treated by curettage and photodynamic therapy. *Clin Exp Dermatol* 31: 228-231.

Mass SM, Lombardi MP, Van Essen AJ et al. 2009. Phenotype and genotype in 17 patients with Goltz-Gorlin Syndrome. *J Med Genet* 46: 716-720.

Reddy J, Laufer MR. 2009. Congenital Anomalies of the female reproductive tract in a patient with Goltz syndrome. *J Pediatr Adolesc Gynecol* 22: 71-72.

Sacoer MF, Motswaledi MH. 2005. Three cases of focal dermal hypoplasia (Goltz syndrome). *Clin Exp Dermatol* 30: 35-37.

Shimaoka Y, Hatamochi A, Hamasaki Y et al. 2009. Severe focal dermal hypoplasia in a female patient transmitted from a mildly affected mother. *J Dermatol* 36(3):181-3.

Suskan E, Kurkcuoglu N, Uluoglu O. 1990. Focal dermal hipoplasia (Goltz syndrome) with horseshoe kidney abnormality. *Pediatr Dermatol* 7: 283-286.

Sutton V, Veyver I. 2013. Focal Dermal Hypoplasia. *University of Washington, Seattle*. [online] Available at: <http://www.ncbi.nlm.nih.gov/books/NBK1543/> [Accessed 19 Aug. 2015].

Wang X, Sutton VR, Peraza-Llanes OJ et al. 2007. Mutations in X-linked *PORCN*, a putative regulator of Wnt signaling, cause focal dermal hypoplasia. *Nat Genet* 39:836–838.

Figures

Figure 1. Left image: a frontal view of the patient. Right image: right deltoid region. Permission was obtained from the parents for presentation.

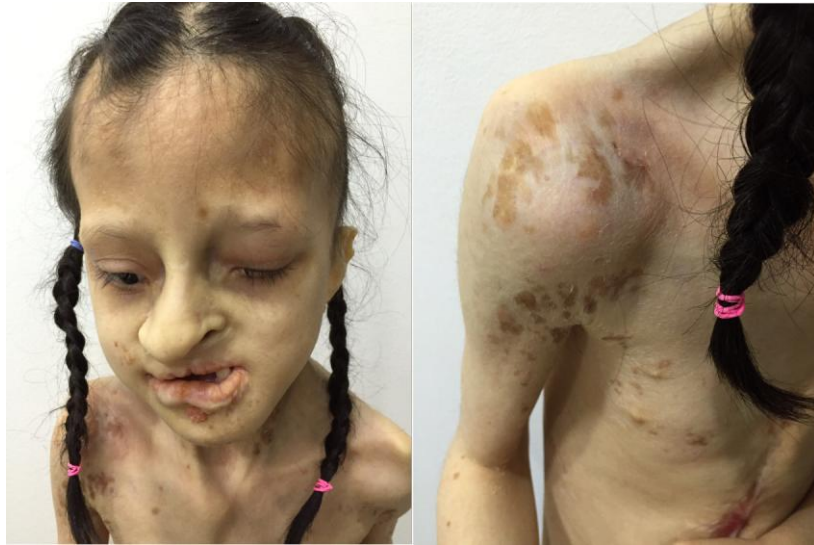Figure 2. Left image: the patient's right hand. Right image: the patient's left hand. Permission was obtained from the parents for presentation.

Figure 3. *PORCN* gene analysis demonstrating the heterozygous mutation NM_203475.2(*PORCN*):c.67C>T(p.Gln23*). Image courtesy of Centogene.

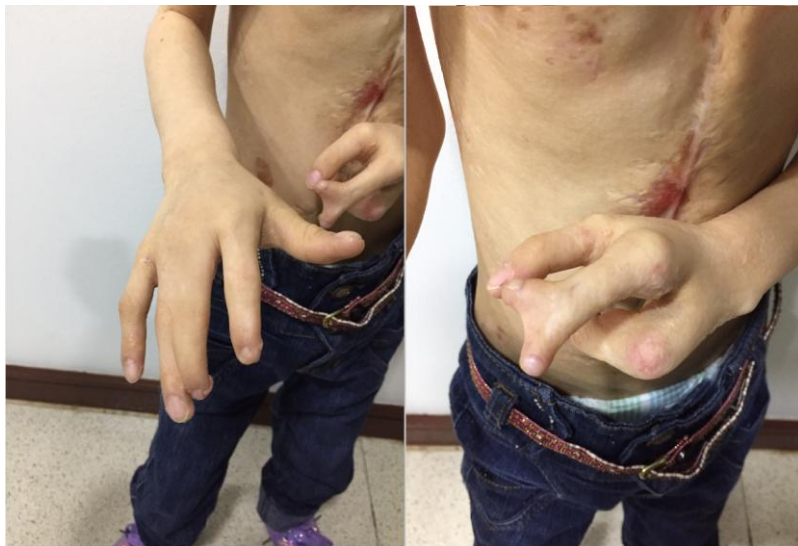Table

Table 1. Phenotypical comparison between FDH patients (Mass et al 2009).

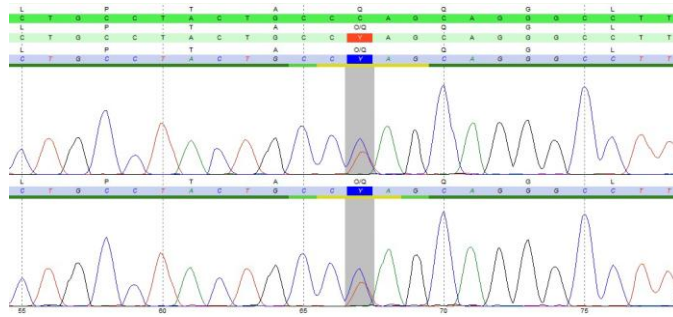
Patients with FDH	17	1
Reference	Maas et al.	Present report
Gender	m, f	f
Mutation in <i>PORCN</i> gene	14/17	Present
Height <P3-P10	11/17	Yes
Sparse scalp hair	13/17	Yes
Unilateral microphthalmia	7/17 Unilateral	Unilateral (left eye)
Unilateral Coloboma	6/17 Unilateral	Unilateral (right eye)
Cleft lip/palate anomalies	4/17	Both present
Oligodontia	4/17	Present
Acral abnormalities	15/ 17	Four limbs affected
Oligodactyly	13/17	Present
Syndactyly	11/17	Present
Nail hypoplasia	14/17	Present
Skin hipoplasia	17/17	Present
Papillomas	9/17	Present
Severe intellectual disability	1/17	Present



cga_12146_AA_F1



cga_12146_AA_F2



cga_12146_AA_F3