

Novel homozygous *PCK1* mutation causing cytosolic phosphoenolpyruvate carboxykinase deficiency presenting as childhood hypoglycemia, an abnormal pattern of urine metabolites and liver dysfunction



Päivi Vieira ^{a,*,1}, Jessie Cameron ^{b,1}, Elisa Rahikkala ^c, Riikka Keski-Filppula ^c, Lin-Hua Zhang ^d, Saikat Santra ^e, Allison Matthews ^d, Päivi Myllynen ^f, Matti Nuutinen ^a, Jukka S. Moilanen ^c, Richard J. Rodenburg ^g, Arndt Rolfs ^{h,i}, Johanna Uusimaa ^{a,j,2}, Clara D.M. van Karnebeek ^{d,k,2}

^a PEDEGO Research Unit, University of Oulu, Clinic for Children and Adolescents, Oulu University Hospital, Oulu, Finland

^b Genetics and Genome Biology, Peter Gilgan Center for Research and Learning, 686 Bay Street, Toronto, Ontario M5G0A4, Canada

^c PEDEGO Research Unit, Clinical Genetics, University of Oulu, Medical Research Center Oulu, Department of Clinical Genetics, Oulu University Hospital, Oulu, Finland

^d Department of Pediatrics, Centre for Molecular Medicine and Therapeutics, BC Children's Hospital Research Institute, University of British Columbia, Vancouver, Canada

^e Department of Clinical Inherited Metabolic Disorders, Birmingham Children's Hospital, Steelhouse Lane, Birmingham B4 6NH, United Kingdom

^f Northern Finland Laboratory Centre Nordlab, Oulu University Hospital, Oulu, Finland

^g Radboud Center for Mitochondrial Medicine, Department of Pediatrics, Translational Metabolic Laboratory, Radboud University Medical Center, Nijmegen, The Netherlands

^h Centogene AG, The Rare Disease Company, Rostock, Germany

ⁱ Albrecht Kossel Institute for Neuroregeneration, University of Rostock, Germany

^j Medical Research Center Oulu and Biocenter Oulu, University of Oulu, Finland

^k Department of Pediatrics, Emma Children's Hospital, Academic Medical Centre, Amsterdam, The Netherlands

ARTICLE INFO

Article history:

Received 10 December 2016

Received in revised form 3 February 2017

Accepted 4 February 2017

Available online 6 February 2017

Keywords:

Child

Impaired gluconeogenesis

Recurrent hypoglycemia

Autosomal recessive

ABSTRACT

Clinical and laboratory data were collected from three Finnish patients including a sibling pair and another unrelated child with unexplained childhood hypoglycemia. Transient elevation of alanine transaminase, lactate and tricarboxylic acid cycle intermediates, especially fumarate, were noticed in urine organic acid analysis. Exome sequencing was performed for the patients and their parents. A novel homozygous *PCK1* c.925G>A (p.G309R) mutation was detected in all affected individuals. COS-1 cells transfected with mutant *PCK1* transcripts were used to study the pathogenic nature of the detected variant. The COS-1 transfected cells showed the mutant gene to be incapable of producing a normally functioning cytosolic phosphoenolpyruvate carboxykinase (PEPCK) enzyme. This report further delineates the clinical phenotype of isolated cytosolic PEPCK deficiency and offers a metabolic pattern helping to recognize these patients. Cytosolic PEPCK deficiency should be considered in the differential diagnosis of children presenting with hypoglycemia, hepatic dysfunction and elevated tricarboxylic acid intermediates in urinary organic acid analysis.

© 2017 Elsevier Inc. All rights reserved.

1. Introduction

Gluconeogenesis is an enzymatic process responsible for ensuring the availability of glucose for the needs of the body during prolonged periods of inadequate carbohydrate intake. The liver is mainly

responsible for gluconeogenesis, for example by catabolizing glucogenic amino acids. Phosphoenolpyruvate carboxykinase (PEPCK, EC 4.1.1.32) catalyzes part of the cataplerotic process where the 4- and 5-carbon intermediates formed in the catabolism of amino acids are removed from the tricarboxylic acid (TCA) cycle. PEPCK has two isoforms, cytosolic PEPCK-C (MIM 261680) and mitochondrial PEPCK-M (MIM 261650).

Mitochondrial PEPCK deficiency has been described in a few cases, but none have been defined at the molecular level. In all cases, diagnosis was made by deficient PEPCK activity in fibroblasts, which has 100% PEPCK-M isoform [1–4]. The general clinical presentations were hypotonia, hepatomegaly, failure to thrive, lactic acidosis and hypoglycemia. Deficiency of the cytosolic form of the PEPCK is an even rarer inherited metabolic disorder of impaired gluconeogenesis caused by mutations in *PCK1* (phosphoenolpyruvate carboxykinase, MIM 614168). Previous publications on biochemically confirmed cytosolic PEPCK deficiency

Abbreviations: ACMG, American College of Medical Genetics and Genomics; ALT, Alanine aminotransferase; CADD, Combined Annotation Dependent Depletion; MAF, Minor allele frequency; OAA, Oxaloacetate; PC, Pyruvate carboxylase; PEP, Phosphoenolpyruvate; PEPCK, Phosphoenolpyruvate carboxykinase; RI, Reference interval; TCA, Tricarboxylic acid; WES, Exome sequencing.

* Corresponding author at: Clinic for Children and Adolescents, Oulu University Hospital, PO BOX 23, FI-90029 Oulu, Finland.

E-mail address: paivi.vieira@fimnet.fi (P. Vieira).

¹ Contributed equally.

² Contributed equally for the senior authorship.

have described a severe clinical picture with persistent neonatal hypoglycemia, lactic acidosis and liver failure, leading to neurological degeneration [5–8]. Only recently, there were two reports published on genetically confirmed deficiency (i.e. due to recessive *PCK1* mutations). The first was a sibling pair who had the cytosolic PEPCK deficiency either in conjunction with Smith-Magenis syndrome or *N*-methyl-D-aspartate (NMDA) receptor glutamate insensitivity [9]. The second was an isolated PEPCK deficiency due to homozygous *PCK1* deletion presenting with transient severe liver failure (including a biochemical profile of hyperammonemia, lactic acidosis and elevated TCA metabolites) elicited by gastroenteritis responsive to a dextrose infusion [10]. Infections and fasting have been suggested to be driving forces for symptomatic periods.

Here we further expand the phenotype by reporting the data of three previously healthy individuals (2 siblings and 1 unrelated singleton) with a novel homozygous *PCK1* mutation who presented with hypoglycemia in early childhood, mostly without an obvious predisposing or eliciting factor.

2. Methods

2.1. Study subjects

The patients were seen at the Clinic for Children and Adolescents and the Department of Clinical Genetics of Oulu University Hospital in 2013–2016 (patients 1.1), 2015–2016 (patient 1.2) and 2014–2016 (patient 2). Their examinations included clinical and laboratory assessments, biochemical and molecular genetic analyses. All procedures were in accordance with the ethical standards of the responsible committee on human experimentation (institutional and national) and with the Helsinki Declaration of 1975, as revised in 2000. Prior to the study, the parents gave written informed consent for their children to participate in the study approved by the Ethics Committee of the Northern Ostrobothnia Hospital District (permit no: 51/2008, and the amendments 2011 and 2014).

2.2. DNA extraction

DNA was extracted from the peripheral blood of the three affected patients, their healthy parents and the two healthy unaffected siblings using standard methods, based on the QIAasympphony DSP DNA Mini Kit (Qiagen, Valencia, CA) on the QIAasympphony instrument. Prior to the analysis the DNA quality and concentration was determined photometrically (OD260/OD280 1.8–2.0).

2.3. Exome sequencing (WES) and Sanger analysis

WES was performed commercially in Centogene AG (Rostock, Germany), in concordance to the provisions of the German Gene Diagnostic Act (Gendiagnostikgesetz) and the General Data Protection Act (Bundesdatenschutzgesetz) to guarantee the confidentiality and protection of data. Sequencing was performed using Illumina's Nextera Rapid Capture Exome Kit and HiSeq4000 sequencers (Illumina, Inc., San Diego, CA). Data was processed using bcl2fastq software 2.17.1.14 (Illumina, Inc., San Diego, CA), and fed to an in-house pipeline based on the 1000 Genomes Project data and Genome Analysis Toolkit (GATK) best practice recommendations. Variants were called using Burrows-Wheeler Alignment (BWA) software with the Maximal Exact Matches (MEM) algorithm and GATK HaplotypeCaller, freebayes and samtools. Variants were annotated using Annovar Alamut version 2.4.5 (Interactive Biosoftware, Rouen, France) and in-house ad hoc bioinformatics tools and compared to the in-house mutation database (Centomd®), The Human Gene Mutation Database (HGMD®), and ClinVar¹⁶. Variants were filtered to keep only those with $\geq 10\times$ depth of coverage, $\geq 20\%$ of total reads and $< 1\%$ in the Exome Aggregation Consortium database (ExAC, <http://exac.broadinstitute.org>), and

Centomd® (<http://www.centomd.com>). Prioritized variants were evaluated based on mode of inheritance and compatibility with the clinical phenotype provided for the index. All clinical features provided were used for each individual case, and, in addition, the HPO ontology was implemented to classify the patient phenotypes. Selected candidate pathogenic, likely pathogenic, and VUS variants were confirmed by conventional PCR amplification and Sanger sequencing. Sanger sequencing of the identified *PCK1* mutation of further family members was performed to confirm the segregation of the variant with the disease phenotype.

2.4. *PCK1* G309R plasmid construction, transfection and PEPCK enzyme activity measurements

Human cytosolic phosphoenolpyruvate carboxykinase 1 (*PCK1*) full-length cDNA (GenBank accession # NM_002591) was cloned in pcDNA3.1 mammalian expression vector (GenScript). To create the G309R mutant *PCK1*, a nucleotide fragment containing *PCK1* c.925A (p.309R) was synthesized (GenScript), and then used to replace the wild type *PCK1* sequence by subcloning. Another mutant *PCK1* with a 12 bp deletion (c.1319_1330del GTGTCCTCTAG; p.440_444del GVPL) was created as described previously [10], and used as a negative control in the present study. All cloned mutants were confirmed by Sanger sequencing. COS-1 cells were transfected with pcDNA3.1 plasmids using lipofectamine 2000 reagent (Life Technologies) for 48 h. The whole cell lysates were used for Western Blot analysis and for PEPCK enzyme activity measurements. PEPCK enzyme measurements were performed in cells as previously described [10].

2.5. Western blot

Western blot analysis of PEPCK protein was performed as described previously [10]. Briefly, $\sim 20\ \mu\text{g}$ of protein from COS-1 cell lysates was fractionated by electrophoresis through a 10% SDS polyacrylamide gel, transferred to PVDF membrane, and then immunoblotted with polyclonal anti-PCK1 antibody (Proteintech; 16754-1-AP) at a 1:1000 dilution. GAPDH was immunoblotted with anti-GAPDH antibody (Millipore, MAB374; 1:5000 dilution) on the same membranes as a loading control.

3. Results

3.1. Case reports

Patient 1.1 (Fig. 1, family 1, affected individual II-3), is the third child of distantly consanguineous parents of Finnish origin, born at term after an uncomplicated pregnancy with Apgar scores of 9/10. She needed a glucose infusion during the first 24 h of life due to low blood glucose levels of 0.9 mmol/l (reference interval RI 4.2–6.3 mmol/l), tested because of tremor and irritability. Her growth and psychomotor development were normal. At the age of 14 months she was noticed to be unusually drowsy and poorly responsive when waking up in the morning after an overnight fast of about 12 h. The drowsiness did not resolve with more sleep, so an ambulance was called. She was able to drink a bit of milk before the arrival of the ambulance, after which the glucose was measured at 1.8 mmol/l. She had no signs of infection, and infection parameters remained low. At admission, base excess was -11 and pH 7.33. Blood lactate and alanine aminotransferase (ALT) were mildly elevated (Table 1). Plasma ammonia was 25 $\mu\text{mol/l}$ (normal $< 50\ \mu\text{mol/l}$). In plasma quantitative amino acid analysis glutamine was slightly elevated while citrulline and arginine were within normal ranges (Table 1). Semiquantitative analysis of urine organic acids by gas chromatography/mass spectrometry was performed two weeks later, after a 20 h fasting test during which blood glucose was 3.2 mmol/l. Urine organic acids demonstrated prominent TCA cycle metabolites (Table 1): especially fumarate but also succinate and 2-ketoglutarate. 3-hydroxybutyrate excretion was intermediately increased while several dicarboxylic acids,

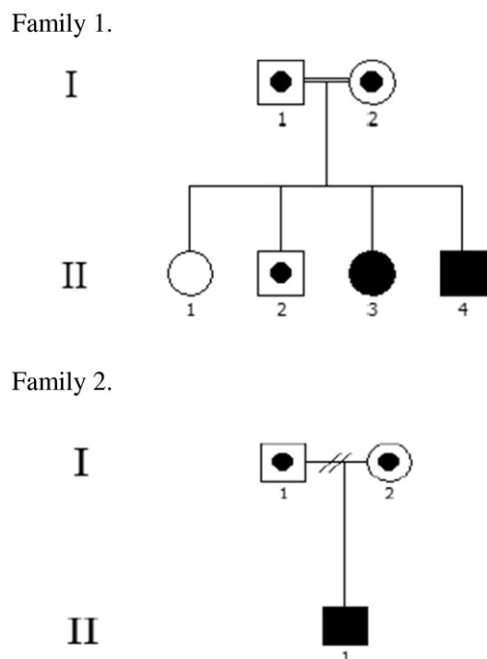


Fig. 1. The pedigrees of family 1 and 2. The parents of the family 1 are distantly consanguineous. The healthy parents of both families and the healthy older brother of family 1 are heterozygous carriers of the *PCK1* p.G309R mutation. The healthy older sister in family 1 does not carry the mutation. The affected children carry the *PCK1* p.G309R mutation in a homozygous state.

especially sebacate, were markedly elevated. Excretion of hydroxy-dicarboxylic acids was also elevated probably due to ketosis. In addition, glutarate and 2-hydroxyglutarate were clearly elevated. More detailed metabolic investigations were unremarkable: acylcarnitine profile, pyruvate dehydrogenase complex, respiratory chain enzyme activities and beta-oxidation enzyme measurements in skin fibroblasts, together with molecular analysis for fatty acid oxidation disorders and glutaric aciduria type II (*ACADM*, *ACADS*, *ACADVL*, *CPT1A*, *CPT2*, *ETFA*, *ETFB*, *ETFDH*, *GLUD1*, *HADHA*, *HADHB*, *HMGCL*, *HMGCS2*, *SLC22A5*, *SLC25A20* genes). Brain MRI and spectroscopy were normal. An ultrasound of the liver showed increased size and echogenicity suggestive of diffuse parenchymal damage.

Table 1

The main laboratory findings of the presented patients and a previously published case. Urine organic acids were analyzed using semi-quantitative gas chromatography/mass spectrometry method. Samples for metabolic investigations were collected during the treatment of first hypoglycemic episode except for urine organic acid sample for patient 1.1, which was collected after a 20 h fasting test two weeks after initial hypoglycemia.

	Patient 1.1	Patient 1.2	Patient 2	Patient from Santra et al. [10]
Laboratory test				
Blood lactate (RI 0.33–1.33 mmol/l)	Mildly elevated 2.05 mmol/l	NA	Normal 0.85 mmol/l	Mildly elevated (2.9 mmol/l)
ALT (Normal below 40 U/l)	Mildly elevated 86–316 U/l	Mildly elevated 77 U/l	Mildly elevated 52 U/l	Grossly elevated 10,003 U/l
Plasma amino acids				
Glutamine	Mildly elevated 1087 μ mol/l (RI 263–904)	Normal 508 μ mol/l (RI 263–904)	Very mildly elevated 794 μ mol/l (RI 304–637)	Grossly elevated 1731 μ mol/l (RI 333–809)
Citrulline	Normal 14 μ mol/l (RI 8–34)	Mildly decreased 6 μ mol/l (RI 8–34)	Normal 21 μ mol/l (RI 8–42)	Mildly decreased 5 μ mol/l (RI 8–47)
Arginine	Normal 59 μ mol/l (RI 13–113)	Mildly decreased 12 μ mol/l (RI 13–113)	Normal 21 μ mol/l (RI 13–119)	Mildly decreased 10 μ mol/l (RI 12–112)
Urine organic acids				
Lactate	High	High	High	Not increased
Fumarate	High	High	High	High
Succinate	High	High	Normal	High
2-ketoglutarate	High	High	Mildly elevated	High
3-hydroxybutyrate	Slightly increased	Highly increased	Not detected	Slightly increased

As a precaution, oral riboflavin (100 mg b.i.d.) and carnitine (50 mg b.i.d.) were introduced, along with instructions of a low fat, high carbohydrate diet with frequent feedings.

During the next two months, ALT and plasma glutamine were intermittently elevated (up to 316 U/l and 940 μ mol/l, respectively) but normalized as did the appearance of the liver and urine organic acids profile. During a respiratory infection at the age of 2 years 9 months, a low level of blood glucose (2.1 mmol/l) was noted with a glucometer at home. She was treated promptly with carbohydrates, and ALT stayed normal. She is currently 5.1 years with normal development and growth, with weight at the 50th percentile, and no further episodes of hypoglycemia. She has been given instructions of regular carbohydrate intake and additional glucose polymer (Fantomalt®) during rigorous exercise and illness or other times of fasting (formal sick day regimen) by the dietitian.

Patient 1.2 (Fig. 1, family 1, affected individual II-4), is the younger male sibling of patient 1, the fourth child of the family. He was born without complications and had no significant health issues until the age of 15 months, when he was noticed to be poorly responsive in the morning after a fast of about 13 h, without an apparent reason. Blood glucose of 0.8 mmol/l was measured at home. Blood glucose at the hospital was 1.4 mmol/l after some oral dextrose intake, and 3.6 mmol/l after the intravenous dextrose was started. ALT was mildly elevated (Table 1), but ammonia was normal (30 μ mol/l). Similarly to his sister, semiquantitative urine organic acid analysis demonstrated prominent TCA cycle metabolites; particularly fumarate. Also succinate and 2-ketoglutarate were elevated. The amounts of lactate and 3-hydroxybutyrate were prominent and several dicarboxylic acids were clearly elevated. Several 3-hydroxydicarboxylic acids were present possibly secondary to ketosis. Furthermore, similarly to his sister, glutarate was clearly elevated. Glyceroluria was not detected. Plasma glutamine was normal but citrulline and arginine were low (Table 1). Base excess was -10.3 and pH 7.32. Free fatty acids were elevated (2.21 mmol/l; RI 0.08–0.70 mmol/l).

The size of the liver was at the upper normal limit 3 months later, with normal echogenicity and ALT. His psychomotor development continued according to the expectations for age with no further episodes of hypoglycemia to date (31 months of age), with normal growth, the weight being at the 55th percentile.

Patient 2 (Fig. 1, family 2, affected individual II-1), is the first child of a Finnish family unrelated to the previous patients. He was born at

39⁺⁴ weeks of gestation by urgent *caesarean* section due to non-progressing labour. The Apgar scores were 9/9 and his health was normal until the age of 4.5 years when he had a seizure in the morning. Blood glucose was measured at 1.2 mmol/l by the ambulance personnel, and 6.3 mmol/l in the hospital after intravenous dextrose was started. He had no signs of infection but was mentioned to have been running around actively the night before. Base excess was -5.2 and pH 7.32. Lactate, pyruvate and ammonia were normal. Free fatty acids were elevated to 2.18 mmol/l and ALT was slightly above normal. Similarly to the two other patients, semiquantitative urine organic acid analysis demonstrated prominent TCA cycle metabolites of which particularly fumarate was high. Also 2-ketoglutaric acid was clearly elevated and lactate was prominent. However, unlike the two other patients, no ketone bodies were detected and the amounts of dicarboxylic acids were low. Also, glutarate was absent. In plasma, glutamine was slightly elevated, while citrulline and arginine were within normal range (Table 1). Control sample for plasma amino acids was taken two months later following overnight fasting, and glutamine was still marginally elevated (689 $\mu\text{mol/l}$; RI 304–637 $\mu\text{mol/l}$). At the same time urine organic acids showed some fumarate but the amount was no longer clearly abnormal. A mitochondrial disorder was suspected but extensive metabolic investigations including beta-oxidation, mitochondrial respiratory chain enzymes, and pyruvate dehydrogenase complex enzymatic activity from cultured fibroblasts were normal. The patient is now 6.8 years with normal development and growth, the weight being at the 50th percentile, with no further episodes of hypoglycemia. He was given the same instructions about extra carbohydrate intake as patients 1.1 and 1.2.

3.2. WES and Sanger sequencing

Trio WES analysis identified a homozygous missense variant in *PCK1* c.925G>A (NM_002591, chr20:56,138,747 (hg19), rs201186470) resulting in an amino acid substitution p.G309R (ENST00000319441) in all three affected children. The variant is located in a highly conserved nucleotide and amino acid position in exon 6 of *PCK1*. Software analyses (Polyphen-2, SIFT, MutationTaster and Align-GVGD) predicted this variant to be probably damaging with a CADD score of 24.3. The variant is present in the Exome Aggregation Consortium (ExAC) database with an overall minor allele frequency (MAF) of 0.00101 including one homozygous individual. In the Finnish population (ExAC) MAF was 0.009828. The variant is classified as a variant of uncertain significance (class 3) according to recommendations of ACMG.

Sanger sequencing confirmed the presence of this variant in a homozygous state in the affected individuals and in a heterozygous state in their healthy parents (Fig. 1).

3.3. *PCK1* protein expression and PEPCK enzyme activity in transfected COS-1 cells

To investigate the pathogenicity of this p.G309R mutation, *PCK1* was overexpressed in COS-1 cells for enzyme activity analysis (Fig. 2 and Supplemental material). The Western blot showed that all transfected *PCK1* constructs were well expressed in COS-1 cells, but mutant G309R protein appeared to be less abundant compared to the wild type *PCK1* suggesting this mutation might influence expression and/or stability.

Measurement of total PEPCK enzyme activity in COS-1 cells had previously demonstrated a low endogenous activity [10], data shown in Table 2. COS-1 cells were transfected with empty pcDNA3.1 vector, wild type *PCK1*, mutants *PCK1* p.G309R and p.GVPLV123V (patient details previously published [10]). The empty vector transfected cells showed a low PEPCK enzyme activity comparable to native COS-1 cells. Transfection with wild type *PCK1* produced an increase in PEPCK enzyme activity that could not be replicated by either of the mutant *PCK1* constructs. This confirmed that the newly identified mutant *PCK1* p.G309R is incapable of producing a normally functioning cytosolic




Fig. 2. *PCK1* protein expression in transfected COS-1 cells. Vector: pcDNA3.1 empty vector; WT: wild type *PCK1*; G309R: Mutant *PCK1*; Del: Mutant *PCK1* with 12-bp deletion [10]. GAPDH: Glyceraldehyde 3-phosphate dehydrogenase, as a loading control.

PEPCK enzyme, similar to the previously published p.GVPLV123V mutant.

4. Discussion

PEPCK is the rate-controlling step in the gluconeogenic pathway, converting oxaloacetate (OAA) into phosphoenolpyruvate (PEP) and carbon dioxide [11]. OAA is formed from pyruvate in the mitochondria, by pyruvate carboxylase (PC, EC 6.4.1.1). PEPCK decarboxylates and phosphorylates OAA using GTP. PEP is then converted into glucose in the cytosol. The subcellular location of PEPCK is variable by species. For example, in human liver, there is an equal amount of mitochondrial and cytosolic PEPCK while in mouse liver, 90% of the PEPCK is cytosolic [12]. The substrates for gluconeogenesis can be lactate or pyruvate/alanine. If lactate is the substrate, the different distribution of PEPCK isoforms in the liver in these two species will dictate the route OAA takes to glucose: lactate is converted to pyruvate by LDH; NADH generated is used at a later stage. Pyruvate cannot be converted to PEP by pyruvate kinase as the reaction is irreversible under intracellular conditions. PC in the mitochondria catalyzes the first reaction (ATP required) and PEPCK the second reaction (GTP required). In human liver, where there is 50% mitochondrial PEPCK, PEPCK-M can convert OAA to PEP and transport it out of the mitochondria. In mouse liver, where there is much less PEPCK-M, gluconeogenesis from lactate must occur via PEPCK-C. The mitochondrial OAA can be converted to aspartate and exit the mitochondria via the glutamate:aspartate shuttle. Studies show that deletion of PEPCK-M in mouse liver has little impact, as expected; while deletion of PEPCK-C results in a loss of gluconeogenesis [13].

When pyruvate or alanine is the source, these 'oxidized' substrates require the production of cytosolic NADH by other means. As there is no OAA transporter, OAA is converted to malate in the mitochondria, transported out of the mitochondria via the malate:alpha-ketoglutarate transporter and then reconverted back to OAA in the cytosol, releasing the cytosolic NADH required for later steps. The roles of PEPCK-C and PEPCK-M in gluconeogenesis can therefore be quite complex depending on availability of the two isoforms in different tissues and species. The current report contributes to insights in the role of the cytosolic form

Table 2

PEPCK enzyme activity is shown for COS-1 cells transfected with empty vector, wild type *PCK1* and mutant *PCK1* (p.GVPLV123V mutant and p.G309R mutant). Enzyme activity is shown \pm standard error, with the number of replicates in parentheses.

COS-1 transfection experiment	PEPCK activity (nmol/mg/min)
COS-1	0.11 \pm 0.01 (3)
COS-1 + empty vector	0.16 \pm 0.02 (3)
COS-1 + wildtype <i>PCK1</i>	7.62 \pm 2.04 (3)
COS-1 + <i>PCK1</i> p.G309R mutant	0.18 \pm 0.04 (3)
COS-1 + <i>PCK1</i> p.GVPLV123V mutant	0.16 \pm 0.03 (3)

by describing and expanding the phenotypic spectrum at a clinical and biochemical level for the human deficiency state.

Limited information has been available about the possible spectrum of clinical symptoms in cytosolic PEPCK deficiency. Previous reports have described severe neonatal or infantile onset hypoglycemia with major biochemical abnormalities [5–8]. The three cases presented here expand the phenotype to childhood presentation in which the liver dysfunction is milder and hyperammonemia may be absent. The predisposing factors were not obvious in most of these hypoglycemic episodes. These previously healthy cases also presented at an older age than other published cases; patient 2 at the age of 4.5 years. One of the presented cases (1.2) did need additional glucose intake as a newborn. Infants are especially vulnerable to disorders in energy availability, but the triggers for hypoglycemic episodes in older children without earlier problems remain to be investigated.

In adipose tissue, PEPCK-C is glyceroneogenic [14], producing glycerol-3-phosphate during fasting, which allows part of the lipolytic fatty acids to be re-esterified into triglycerides and stored [15]. The defective PEPCK-C activity in this tissue should reduce re-esterification and increase fatty acid output to the blood and potentially their use in the liver with increased ketone body synthesis. In our patients, evidence of PEPCK-C deficiency in adipose tissue includes elevated free fatty acids in the blood and the presence of ketones in urine organic acids. The amount of ketones showed marked variation between patients. The samples were collected at variable time points during the hypoglycemic episode, while the treatment with dextrose was already started, which may have affected the amount of detectable ketone bodies. Some other yet unknown regulatory factors might also be involved and more research is needed on the role of PEPCK-C in various tissues. There were no clinical signs suggesting PEPCK-C deficiency in the adipose tissue; weight and fat distribution were unremarkable in these patients.

This is the first published report of the recessive *PCK1* p.G309R mutation. We provide evidence for a deleterious impact and report on the phenotype comparing it to previous literature cases [9,10]. Furthermore, to aid clinical recognition of this treatable inborn error of metabolism, we propose a biochemical signature of hypoglycemia with high TCA cycle intermediate excretion, especially fumarate, with or without ketonuria, dicarboxylic aciduria and urea cycle dysfunction during metabolic crisis for this type of gluconeogenesis defect. PEPCK enzyme converts oxaloacetate from TCA cycle to phosphoenolpyruvate, thus the impairment of PEPCK leads to the accumulation of TCA cycle intermediates. Previously Santra et al. [10] observed an amino acid profile suggesting a proximal urea cycle defect during acute episode. The findings in plasma amino acids are much milder in our patients but considering the milder phenotype our results with the slight elevation in glutamine and decrease in citrulline and arginine agree well with findings by Santra et al. [10]. It is possible that cytosolic PEPCK deficiency is a disorder with clinical spectrum ranging from early-onset and severe cases to milder late-onset presentations, similarly to many other inborn errors of metabolism.

The reason the clinical phenotype seen in our patients is milder than the previously reported patients could be due to the nature of the mutations. The four amino acid deletion in the patient reported in Santra et al. [10] would likely produce a more impaired protein than the single point mutation identified in the current patients. This could result in earlier and more noticeable clinical symptoms. It is of interest that the MAF of the Finnish cohort was 0.009828 as compared to the overall MAF of 0.00101 in the ExAC cohort, suggesting that this variant is enriched in the Finnish population. There was also one homozygous individual possessing the *PCK1* c.925G>A mutation in the ExAC database. It is possible that this mutation causes a relatively mild phenotype and some patients remain undiagnosed. It is also possible that there are modifying factors in the genome that influence the severity or even penetrance of the phenotype.

As the sibling pair and the other unrelated patient described here possessed the same homozygous *PCK1* mutation, it is possible that all

these patients are very distantly related. The genetic background of Finnish patients is homogenous and a common founder mutation is identified in several recessively inherited diseases in Finland [16]. Recently a congress abstract (SSIEM 2016 poster) described a patient with a compound heterozygous *PCK1* mutation, presenting with hypoglycemia, liver dysfunction and gastrointestinal hemorrhage [17]. The other allele carried the same mutation (p.G309R) as the homozygous mutation reported here.

5. Conclusions

This report expands the phenotype of recessive *PCK1* aberrations and further suggests that cytosolic PEPCK deficiency might be a more common cause of unexplained childhood hypoglycemia than previously thought. With the increasing awareness of this gluconeogenesis disorder and the availability of molecular genetic diagnosis, it is likely that more patients with *PCK1* mutations will be diagnosed in the future.

Supplementary data to this article can be found online at <http://dx.doi.org/10.1016/j.jmgme.2017.02.003>.

Acknowledgments

Funding: Canadian Institutes for Health Research #301221: BC Children's Hospital Research Foundation (1st Collaborative Area of Innovation); and Michael Smith Foundation for Health Research (Scholar Award). We are grateful to Dr. Colin Ross for providing laboratory space and equipment for the transfection studies.

References

- [1] B.H. Robinson, J. Taylor, W.G. Sherwood, The genetic heterogeneity of lactic acidosis: occurrence of recognizable inborn errors of metabolism of pediatric population with lactic acidosis, *Pediatr. Res.* 14 (8) (1980) 956–962.
- [2] B.M. Atkin, M.F. Utter, M.B. Weinberg, Pyruvate carboxylase and phosphoenolpyruvate carboxylase activity in leukocytes and fibroblasts from a patient with pyruvate carboxylase deficiency, *Pediatr. Res.* 13 (1) (1979) 38–43.
- [3] P.T. Clayton, K. Hyland, M. Brand, J.V. Leonard, Mitochondrial phosphoenolpyruvate carboxylase deficiency, *Eur. J. Pediatr.* 145 (1–2) (1986) 46–50.
- [4] J.V. Leonard, K. Hyland, N. Furukawa, P.T. Clayton, Mitochondrial phosphoenolpyruvate carboxylase deficiency, *Eur. J. Pediatr.* 150 (3) (1991) 198–199.
- [5] R.H. Fiser, H.L. Melsner, D.A. Fisher, Hepatic phosphoenolpyruvate carboxylase (PEPCK) deficiency: a new cause of hypoglycemia in childhood, *Pediatr. Res.* 8 (1974) 432.
- [6] O. Sovik, J. Vidnes, S. Falkmer, Persistent neonatal hypoglycaemia: a clinical and histopathological study of three cases treated with diazoxide and subtotal pancreatectomy, *Acta Pathol. Microbiol. Scand. A Pathol.* 83 (1975) 155–166.
- [7] J. Vidnes, O. Sovik, Gluconeogenesis in infancy and childhood. III. Deficiency of the extramitochondrial form of hepatic phosphoenolpyruvate carboxylase in a case of persistent neonatal hypoglycaemia, *Acta Paediatr. Scand.* 65 (3) (1976) 307–312.
- [8] F.A. Hommes, K. Bendien, J.D. Elema, H.J. Bremer, I. Lombeck, Two cases of phosphoenolpyruvate carboxylase deficiency, *Acta Paediatr. Scand.* 65 (2) (1976) 233–240.
- [9] D.R. Adams, H. Yuam, T. Holyoak, K.H. Araja, P. Hakimi, T.C. Markello, et al., Three rare diseases in one sibling pair: *RAI1*, *PCK1*, *GRIN2B* mutations associated with Smith Magenis Syndrome, cytosolic PEPCK deficiency and NMDA receptor glutamate insensitivity, *Mol. Genet. Metab.* 113 (3) (2014) 161–170.
- [10] S. Santra, J.M. Cameron, C. Shyr, L. Zhang, B. Drögemöller, C.J. Ros, et al., Cytosolic phosphoenolpyruvate carboxylase deficiency presenting with acute liver failure following gastroenteritis, *Mol. Genet. Metab.* 118 (1) (2016) 21–27.
- [11] J. Yang, S.C. Kalhan, R.W. Hanson, What is the metabolic role of phosphoenolpyruvate carboxylase, *J. Biol. Chem.* 284 (40) (2009) 27025–27029.
- [12] R.W. Hanson, A.J. Garber, Phosphoenolpyruvate carboxylase. I. Its role in gluconeogenesis, *Am. J. Clin. Nutr.* 25 (10) (1972) 1010–1021.
- [13] R.W. Hanson, Thematic minireview series: a perspective on the biology of phosphoenolpyruvate carboxylase 55 years after its discovery, *J. Biol. Chem.* 284 (40) (2009) 27021–27023.
- [14] F.J. Ballard, R.W. Hanson, G.A. Leveille, Phosphoenolpyruvate carboxylase and the synthesis of glyceride-glycerol from pyruvate in adipose tissue, *J. Biol. Chem.* 242 (11) (1967) 2746–2750.
- [15] C. Forest, J. Tordjman, M. Glorian, E. Duplus, G. Chauvet, J. Quette, et al., Fatty acid recycling in adipocytes: a role for gluconeogenesis and phosphoenolpyruvate carboxylase, *Biochem. Soc. Trans.* 31 (Pt6) (2003) 1125–1129.
- [16] J. Kere, Human population genetics: lessons from Finland, *Annu. Rev. Genomics Hum. Genet.* 2 (2001) 103–128.
- [17] T. Tangeraas, K. Tveten, H. Astrup, T. Rootwelt, P.H. Backe, B. Woldseth, Cytosolic phosphoenolpyruvate carboxylase deficiency (cPEPCK) presenting with gastrointestinal hemorrhage, *JIMD* 39 (Suppl. 1) (2016) S145.